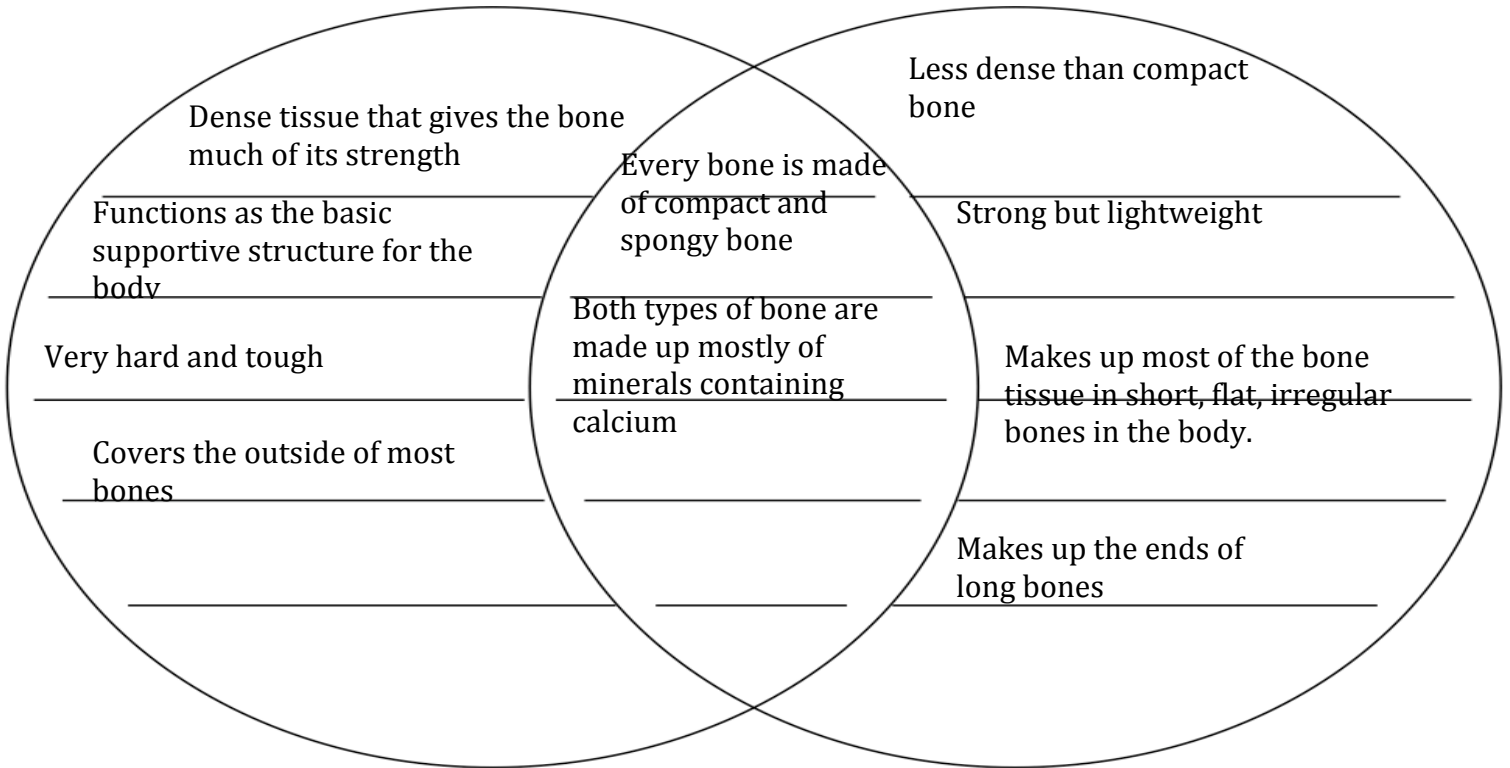


Skeletal Venns

Subject: Compact Bone

Subject: Spongy Bone



Subject: Axial Skeleton

Subject: Appendicular Skeleton

