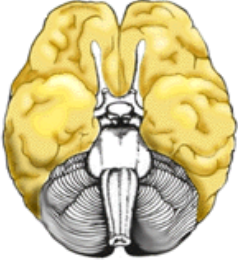
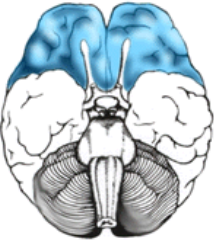




A Guide to Brain Anatomy, Function and Symptoms

Excellent resource: www.waiting.com/brainstem.html
www.neuroscienceforkids.com

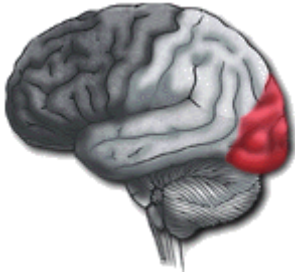Brain Structure	Function	Associated Signs and Symptoms of abnormality
<p>Cerebral Cortex</p>  <p>Ventral View (From bottom)</p>	<p>General Info</p>	
<p>Frontal Lobe</p>  <p>Ventral View (From Bottom)</p>  <p>Frontal Lobe (Side View)</p>	<p>General Info:</p> <p>Prefrontal Cortex</p>	
<p>Parietal Lobe</p> 	<p>Anterior</p> <p>Posterior</p>	

Parietal Lobe

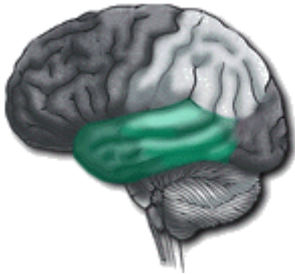Left

Right

Occipital Lobe



Temporal Lobe

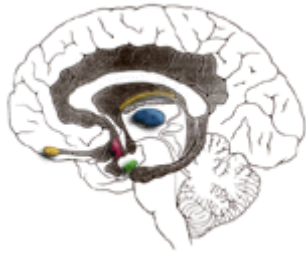


General Info:

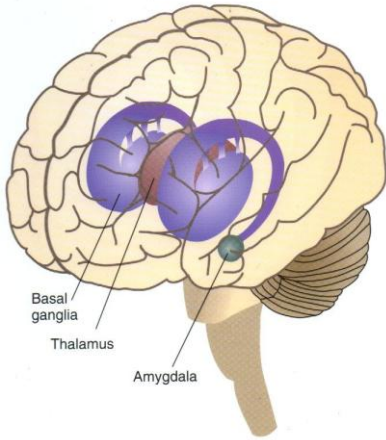
Left Hemisphere

Right Hemisphere

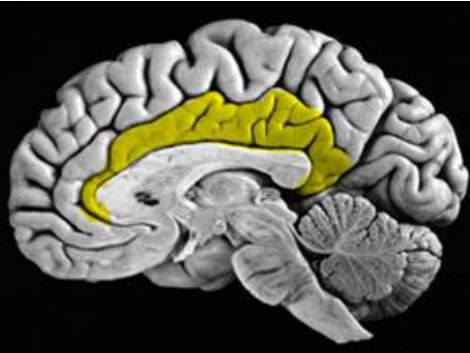Limbic System



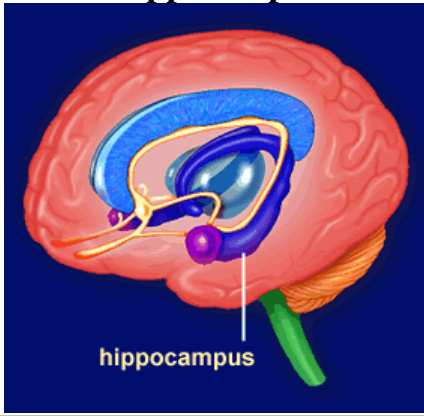
Basal Ganglia



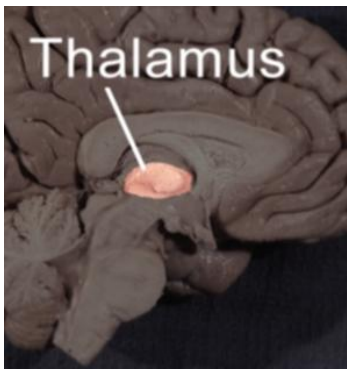
Cingulate Gyrus



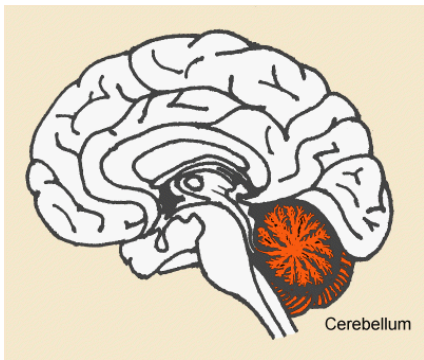
Hippocampus



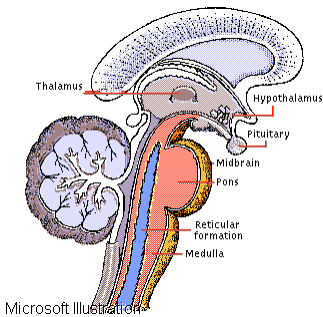
Thalamus



Cerebellum



Brainstem



Medulla Oblongata

Midbrain

Pons